

Use of a sibilant phoneme registration protocol to prevent upper airway collapse in patients with TMD

Gurdev Dave Singh · Steven Olmos

© Springer-Verlag 2007

Abstract Patients with temporomandibular dysfunction (TMD) require antero-posterior (AP) correction of mandibular position inter alia. Determination of the limit of the AP correction using a sibilant phoneme registration (SPR) protocol is essential in not increasing muscular tonus. The aim of this study is to investigate the effect of a SPR protocol on the upper airway. Using acoustic pharyngometry data, mean airways of 46 adults undergoing treatment for TMD were reconstructed in 3-D and analyzed using finite element analysis and principal components analysis. When the mean baseline functional residual capacity (FRC) airway was compared to the mean collapsed residual volume (RV) airway, a 25% reduction in the 3-D upper airway was demonstrable ($p < 0.01$). When the mean baseline FRC airway was compared to the mean airway with SPR (FRC–SPR), a 12% increase was found at the oropharyngeal junction of the 3-D airway, but this finding failed to reach statistical difference. Similarly, when the mean FRC–SPR airway was compared to the mean RV–SPR airway, the amount of collapse was reduced to 16% but again no statistical difference was found. In contrast, when the mean RV airway was compared to the mean RV–SPR airway, a 15–18% increase was found ($p < 0.05$). It is concluded that the use of a SPR protocol may be useful in improving upper airway RV in patients, during treatment for TMD.

Keywords Temporomandibular · Pharyngometry · Phonetic · Airway

Introduction

Patients with temporomandibular dysfunction (TMD) require correction of mandibular position, but the ideal position for the mandible remains controversial. Miralles et al. [1] found the amount of freeway space (FS) required depended on the protocol used to measure it. For example, a significantly higher clinical FS value was found using a phonetic method than after swallowing or with the mandible in a relaxed postural position. A sibilant is the hissing or whistling sound heard in the formation of certain letters in speech, such as the letter “s.” A phoneme is the smallest unit of speech that defines one sound from another. Thus, a sibilant phoneme registration (SPR) protocol is colloquially known as a ‘phonetic bite’.

Patients with TMD secondary to temporomandibular joint (TMJ) inflammation (retrodiscitis), disc displacement, or disc dislocation require an antero-posterior (AP) correction inter alia. Understanding the limit of the AP correction is essential in producing jaw relations that will not increase muscle tone. A ‘phonetic bite’ may be able to determine the limit of the AP translation of the mandible. For example, Pound [2] suggested that the body of the mandible assumes an easily recordable, repetitive horizontal, and vertical position when the patient is at the /S/ position during speech. Later, Burnett and Clifford [3] concluded that sibilant phonemes cause a subject to adopt the closest speaking space. Given that protrusion of the mandible beyond this position will produce muscular dysfunction, evaluation of the need for rotational, cant, vertical, and AP corrections can then be done within the neuromuscular

G. D. Singh (✉)
BioModeling Solutions,
20699 NE Glisan Street, Suite #233,
Portland, OR 97024, USA
e-mail: gdsingh27@gmail.com

S. Olmos
TMJ Therapy Research Center,
8030 La Mesa Boulevard, #190,
La Mesa, CA 91941, USA

envelope of movement. Despite the apparent advantage of a SPR protocol, the effect of this method on the patient's airway remains undocumented. Therefore, the aim of this study is to investigate the effect of a SPR protocol on the patient's upper airway. The null hypothesis to be tested is that there are no differences in the patient's upper airway when compared to the best found mandibular position using a SPR protocol. Rejection of the null hypothesis could provide evidence of the efficacy of a SPR protocol in preserving airway patency during TMD therapy. Therefore, a further implication of this rationale is that if a TMD orthotic fabricated to the SPR registration improves the patient's airway during the day, then these benefits may persist if the patient also wears the TMD orthotic while sleeping, similar to a mandibular advancement device, as it is thought that a smaller upper airway probably predisposes to airway collapse during sleep.

Materials and methods

After obtaining appropriate consent, the medical records of 46 adults with a history of TMD were obtained for this study. The participants consisted of 17 men and 29 women aged 16–84 years (mean 42.7 ± 15 years), who presented with symptomatic temporomandibular joint disorders in a clinical practice in San Diego, CA. The TMD ranged from capsulitis with and without disc displacement to chronic degenerative osteoarthritis. Each patient was examined, diagnosed, and treated by the same clinician (SO). The condyle fossa relationships were measured, using standardized sagittal corrected hypocycloidal tomography (Comm-Cat, Imaging Sciences). In addition, using an acoustic pharyngometer (Eccovision, Pembroke, MA), four readings were obtained for all patients [4] representing functional residual capacity (FRC) or end breath airway (normal breathing without any appliances), residual volume (RV) after complete exhalation, FRC at the best found position using a SPR (FRC–SPR), and RV after complete exhalation using a SPR (RV–SPR). All pharyngometer data were reconstructed, and the mean 3-D airways were analyzed using finite element analysis and principal components analysis (PCA) [5, 6].

Finite element analysis

Finite element scaling analysis (FESA) can be used to depict clinical changes in terms of allometry (size-related shape change). Using FESA, the change in form between a reference configuration and target configuration can be viewed as a continuous deformation, which can be quantified based on major and minor strains (principal strains). If the two strains are equal, the form change is

characterized by a simple increase or decrease in size. However, if one of the principal strains changes in a greater proportion transformation occurs in both size and shape. The product of the strains indicates a change in size if the result is not equal to 1. For example, a product >1 represents an increase in size equal to the remainder; 1.09 indicates a 9% increase. Similarly, a product of 0.85 indicates a 15% decrease. The products and ratios can be resolved for individual landmarks within the configuration, and these can be linearized using a log–linear scale. For ease of interpretation, a pseudo-color-coded scale can be deployed to provide a graphic display of size change [6].

Principal components analysis

PCA can be used to compare different groups of patients, with specific characteristics [7]. Normally, a few modes (the principal components) are sufficient to describe all of the shapes approximately. Importantly, the points representing the shapes in the mode space are grouped according to their main characteristics. Thus, PCA is determining axes that account for the maximal variance. If PCA is applied, the two most significant modes can be used for classification/diagnostic purposes [7].

Sibilant phoneme registration protocol

The goal of the SPR method is to reproduce the spatial relationships of the mandible during speaking and is best taken with reduced nociceptive input to the central nervous system. In this study, pulsed radiofrequency therapy (Energex, Orthosonix) was used to reduce or eliminate nociception. The Energex device generates radiofrequency energy in the 460-kHz range. The energy is pulsed, i.e., rapidly cycled on and off at 660 Hz. This device is thought to reduce TMJ pain and to increase maximum mandibular opening and excursion. In the present study, six 15-s treatments to each TMJ were employed: three applications with the mouth closed (lateral capsule) and three with the mouth open (posterior joint space), bilaterally. A round separating device was used as a fulcrum on the anterior teeth to capture resting position between “S” sounds counting from 66 to 77 (Fig. 1). In this study, a round, wooden, disposable cotton tip was used for overbites in the normal range (1–2 mm), as only minimal vertical separation is needed to center the condyle in these cases. The tip of a microbrush applicator was used if a deep overbite ≥ 4 mm was found. If greater vertical dimension changes were found, then a disposable three-way syringe tip was used. If the patient had an anterior open bite, a disposable saliva ejector tube was used. All patients were advised that a separating device would be placed between their front teeth and that, while counting, they would be asked to “freeze”

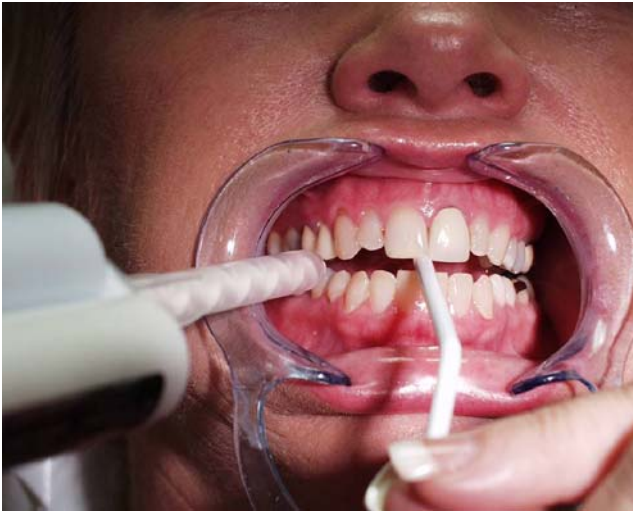

Fig. 1 A round separating device was used as a fulcrum on the anterior teeth to capture resting position between “S” sounds. A round, wooden, disposable cotton tip was used for overbites in the normal range (1–2 mm), and the tip of a microbrush applicator was used if a deep overbite ≥ 4 mm was found. For greater vertical dimension changes, a disposable three-way syringe tip was used, and if the patient had an anterior open bite, a disposable saliva ejector tube was used. A small amount of bite registration material was injected to record the jaw relations

the mandible in space at some point during that time. The goal of this technique was to match the separating device to the amount of anterior teeth separation at rest between these “S” sounds. Bassi et al. [8] found that the minimum speaking space (MSS) appears to be more reliable than the FS parameter, as it is not influenced by the patient’s will.

Placement of the separating device was done very carefully to avoid altering any jaw relationships. Patients were advised that they should not try to “help” the clinician by moving the head or opening the mouth. If the patient was a little too open or slightly overclosed, they were asked to make tiny increments of change, until it was just possible to insert the separating device (Fig. 1). It was imperative that the patient did not move the mandible once the separating device had been placed. Nevertheless, in some cases, it was necessary for the patient to move the tongue to the right or left, if the arch space was too narrow, and the tongue filled the interocclusal space. It was important to have this space clear, so that the bite registration material could be injected completely through to the lingual aspect of the dental arch (Fig. 1). After complete setting, the bite registration material was trimmed, so that it did not extend past the lingual cusps when taking the pharyngometer evaluation to avoid any distortion of oral cavity volume during testing (Fig. 2).

In summary, it was imperative that mandibular position was not altered while using the acoustic pharyngometer, and only recordings fulfilling this criterion were included in

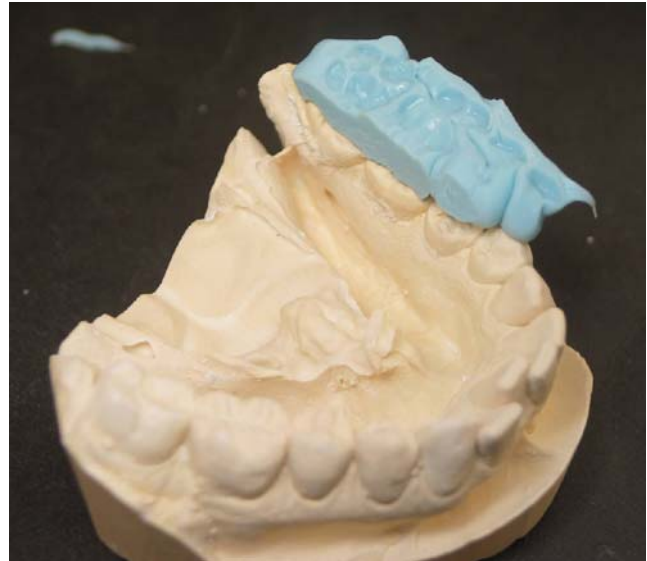

Fig. 2 After complete setting, the (*blue*) bite registration material was trimmed with a scalpel, so that it did not extend past the lingual cusps, when the pharyngometer evaluation was taken

this study. All acoustic pharyngometry was performed in the erect position in all cases at all times with the patient sitting in the same dental chair. The same dental chair was used by the same operator with patients sitting in it with a standardized head position. Although the procedure required a mouthpiece, this did not induce mouth opening, as the mouthpiece design did not have a lingual tab (Fig. 3). In other words, the mandibular position was not altered while using the pharyngometer mouth piece, as far as practically possible (Fig. 4), and therefore, the impact on airway caliber from the acoustic pharyngometry was minimal or absent, as far as practically possible.



Fig. 3 Using a scalpel, the lingual tab was removed from the mouthpiece, which was then used for acoustic pharyngometry

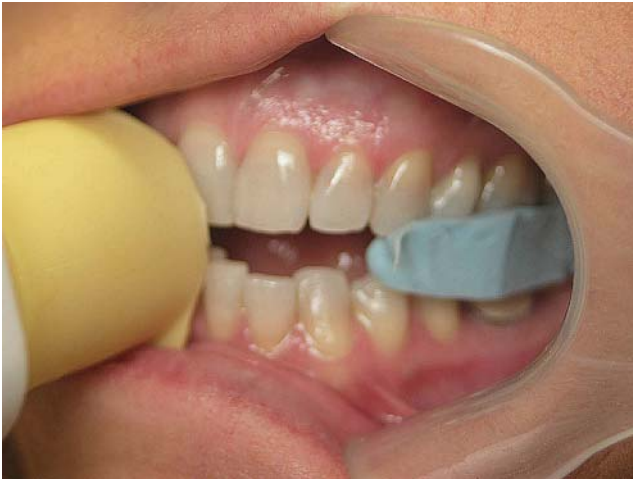

Fig. 4 With the patient gently biting on the (blue) bite registration material in situ, the pharyngometer mouthpiece with the lingual tab removed is carefully maneuvered into position to take the reading

Results

Figure 5 shows a 3-D airway superimposed on a lateral cephalograph for ease of interpretation of the following results.

Finite element scaling analysis

Figure 6 shows the results of pseudo-color FESA of the mean baseline FRC (normal breathing) airway compared to

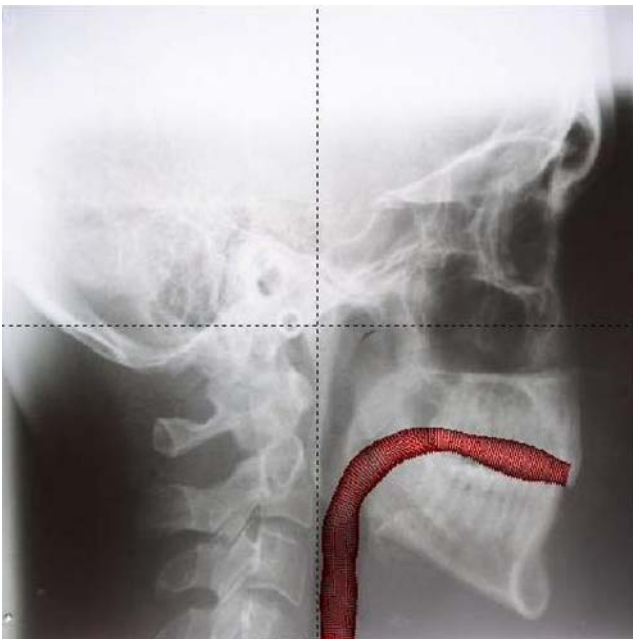

Fig. 5 A 3-D airway reconstructed from acoustic pharyngometry data superimposed on a lateral cephalograph for illustration purposes only. The landmarks used for superimposition include the inter-incisal angle, the oropharyngeal junction, and the glottis, the location of each of which is discernible from pharyngometry data

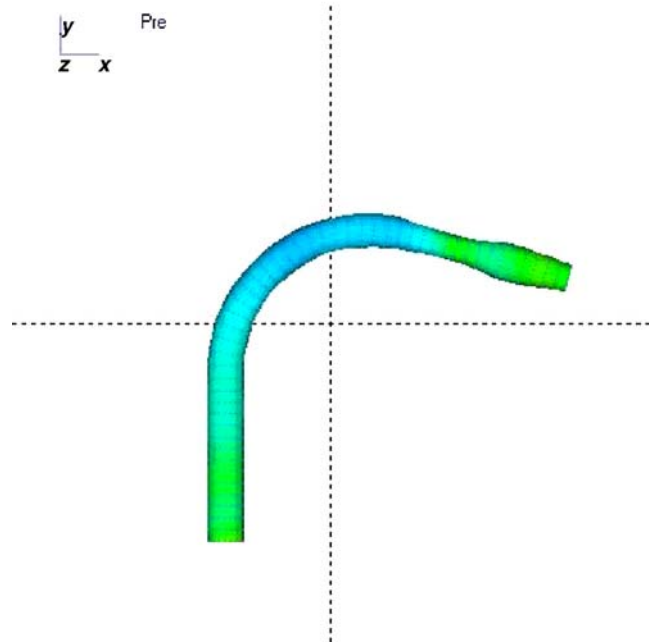
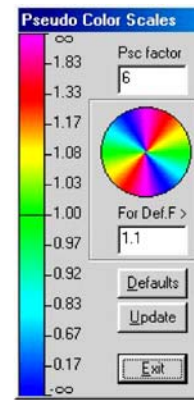


Fig. 6 Pseudo-color FESA results comparing the 3-D mean baseline FRC (normal breathing) airway compared to RV. Using the vertical color scale, the blue regions demonstrate a 25% collapse at RV with respect to FRC

RV. Using the vertical pseudo-color scale, the blue regions demonstrate a 25% collapse of the upper airway at RV with respect to FRC.

Figure 7 shows the results of pseudo-color FESA of the mean baseline FRC compared to the mean FRC–SPR airway (phonetic bite or best found position). The yellow region indicates a 12% airway enhancement at the oropharyngeal junction.

Figure 8 shows the results of pseudo-color FESA of the mean FRC–SPR airway compared to the mean RV airway measurement with the phonetic bite or best found position (RV–SPR). The blue region demonstrates a 16% collapse at RV–SPR relative to FRC–SPR.

Figure 9 shows the results of pseudo-color FESA of the mean collapsed airway at RV compared to RV–SPR. The orange color demonstrates a 15–18% increase in RV–SPR relative to RV.

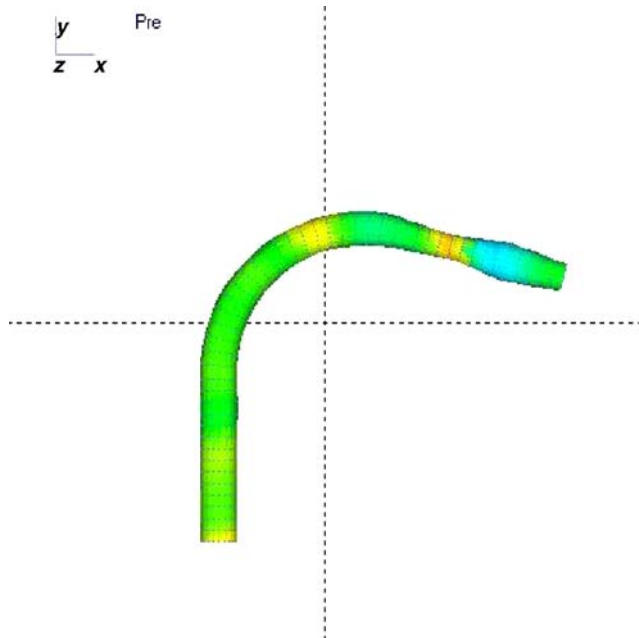


Fig. 7 Pseudo-color FESA results comparing the 3-D mean baseline FRC airway to the mean FRC-SPR airway (phonetic bite or best found position). Using the vertical color scale, the *yellow region* indicates a 12% airway enhancement at the oropharyngeal junction

Principal components analysis

While the above results indicate clinical changes in the 3-D airways, the above data were subjected to statistical analysis using PCA. Figure 10 shows the results of PCA

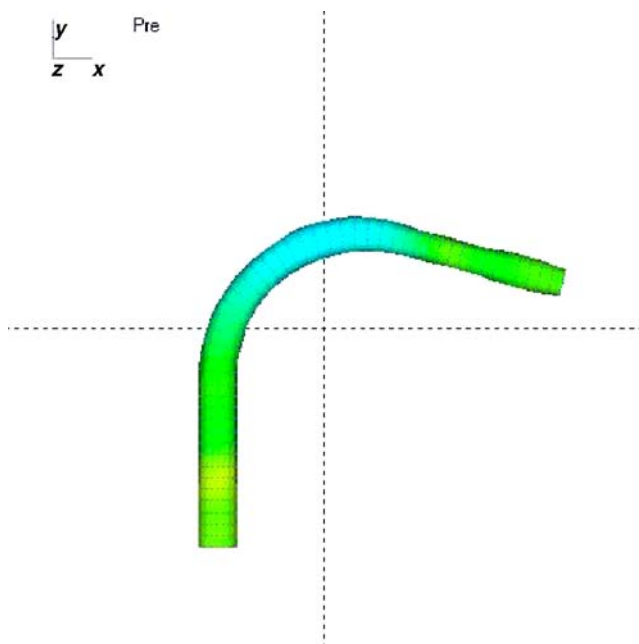


Fig. 8 Pseudo-color FESA results comparing the 3-D mean FRC-SPR airway compared to the mean RV airway measurement with the phonetic bite or best found position (RV-SPR). The *blue region* demonstrates a 16% collapse at RV-SPR relative to FRC-SPR

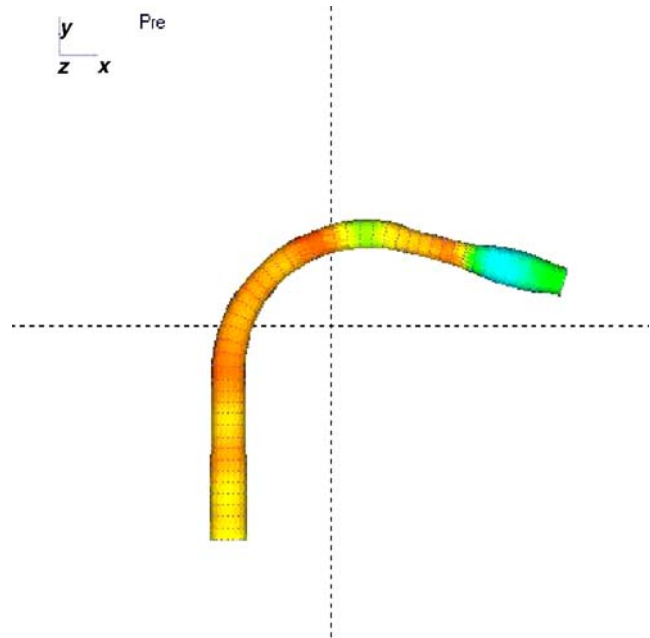


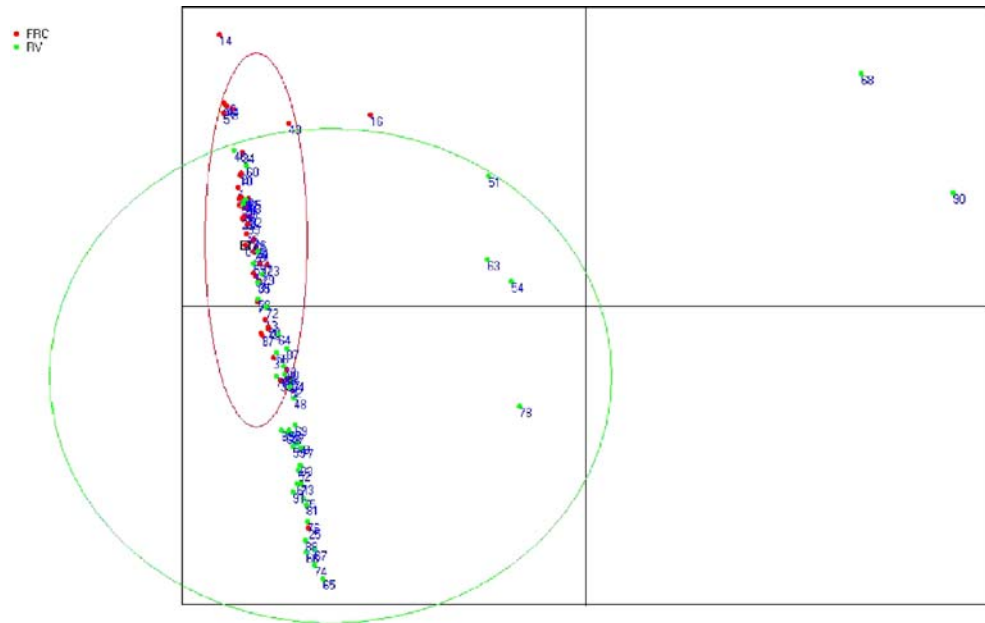
Fig. 9 Pseudo-color FESA results comparing the 3-D mean collapsed airway at RV compared to RV-SPR. The *orange color* demonstrates a 15–18% increase of RV-SPR relative to RV

of baseline FRC (normal breathing) and RV using the first two eigenvalues, which accounted for >91% of the total shape information available. When compared using *t*-tests, the two groups were found to be statistically different ($p=0.004$). The results of PCA of baseline FRC compared to FRC-SPR showed that the first two eigenvalues accounted for >80% of the total shape information available. When compared using *t*-tests, the two groups were not found to be statistically different ($p=0.30$). The results of PCA of FRC-SPR airways compared to RV airways with the phonetic bite (RV-SPR) showed the first two eigenvalues accounted for >77% of the total shape information available. When compared using *t*-tests, the two groups were also not found to be statistically different ($p=0.77$). In contrast, the results of PCA of the airways at RV compared to RV-SPR showed the first two eigenvalues accounted for >89% of the total shape information available. When compared using *t*-tests, the two groups were found to be statistically different ($p=0.003$).

Discussion

Several techniques, such as lateral cephalography, endoscopy with or without the Muller maneuver, endoscopy during sleep with or without nasal continuous positive airway pressure, fluoroscopy, computed tomography scans, magnetic resonance imaging, manometry, and acoustic reflection, have been used to investigate the airway for obstructive sleep apnea syndrome [9]. While the reliability

Fig. 10 PCA of baseline *FRC* (normal breathing) and residual volume (*RV*), using the first two eigenvalues, which accounted for >91% of the total shape information available. The *green dots* represent the 3-D airways of individual patients at *FRC*. The *red dots* represent the 3-D airways of individual patients at *RV*. The labels identify each patient by *number*. When compared using *t*-tests, the two groups were found to be statistically different ($p=0.004$)



of acoustic reflection using the standard operating protocol has been validated [4], previous studies using acoustic pharyngometry data have relied on 2-D analyses [10]. In this study, mean upper airways of 46 adults undergoing treatment for TMD were reconstructed in 3-D and analyzed using finite element analysis and PCA. While this technique for 3-D airway reconstruction is potentially useful, it is simply a mathematical reconstruction based on cross-sectional areas as a function of distance. It is difficult to argue that the 3-D reconstruction represents true anatomy, as shape information is not available through acoustic pharyngometry. Nevertheless, Fig. 5 shows a 3-D airway superimposed on a lateral cephalograph for ease of interpretation of the results.

For this particular study, limited demographic data were available, and importantly, BMI data were not available. Therefore, although this present investigation does not study obstructive sleep apnea (OSA), we were able to make some inferences regarding the potential relevance of the findings to breathing during sleep, although it is possible that the co-existence of OSA in the subjects studied may have confounded the results. Put simply, this is the first paper, to the best of our knowledge, that indicates that there may be an association between TMD and upper airway morphology because even if one assumes that none of the patients had OSA, we demonstrated changes in airway caliber in the awake state, which were present in patients who clinically presented with signs and symptoms of TMD. The clinical relevance of the observed airway changes is that patients with TMD may have silent or latent airway issues that require further investigation. However, the purpose of this article is to demonstrate a simple technique

that will optimize TMJ function and improve the oropharyngeal airway in the production of TMD orthotics. The goal of SPR is to capture a neuromuscular relaxed and airway patent position that is determined by the autonomic nervous system. In this study, each patient was told to count at a normal cadence. As they began to count, the mandible was caught in its upswing and stopped at a position relative for the diameter of the separating device. Therefore, this study investigated the effect of a SPR protocol on 3-D upper airways in patients being treated for TMD. Finite element analysis has been used previously on 2-D and 3-D clinical data with acceptable results [5, 11]. Similarly, PCA has also been used to validate the FESA findings [12]. Therefore, the methodologies of this present study are warranted.

Okeson [13] clarifies why the “S” position is preferable when taking a phonetic bite. In this position, the tongue is relaxed and level relative to maxillo-mandibular tooth relationships. With the mandible in this forward posture, there is a reduction in nociceptive ascending input from the posterior joint space. Furthermore, it is thought that the “S” sound produces a patent airway, while other positions might reduce this relationship. Burnett and Clifford [14] investigated the effect of increased occlusal vertical dimension on mandibular movement during speech in six adults. The closest speaking space, as determined during pronunciation of sibilant speech sounds, was found to decrease, as the vertical dimension was increased by 4 mm in the incisor region. Similarly, Souza and Compagnoni [15] assessed the relation between the speaking space of the /s/ sound and the FS determined by asking subjects to occlude from the postural rest position. A correlation was found between the

speaking space of /s/ and the FS. Konchak et al. [16] studied vertical dimension and FS using kinesiography. They also found a statistical correlation between the S–N/mandibular plane angle and clinical FS, but there was no correlation after transcutaneous electrical nerve stimulator (TENS) stimulation. However, in a similar but more comprehensive study, Rivera-Morales and Mohl [17] questioned the clinical significance of small numerical changes. This contention was supported by Lu et al. [18] whose computer-aided study indicated that the sibilant sounds produce the closest speaking space. The belief that the closest speaking space is smaller than the FS was not supported by that study. More recently, Meier et al. [19] concluded that none of the registration methods studied display clear-cut superiority to the others. Therefore, non-occlusal advantages, such as airway patency, may help the clinician decide on which registration protocol to follow.

Recently, it was reported that the thickness of orthotic devices have little effect on the FS [20], whereas Johnson et al. [21] suggested that the range for FS could vary between 2–7 mm. Konchak et al. [22] noted a tendency for an increase in FS before and after TENS using mandibular kinesiography and electromyography. However, Bassi et al. [8] believe that the MSS appears to be more reliable than the FS, as increasing the thickness of the palate vault causes a marked lowering of the mandible during speech. Woda et al. [23] also argue that habitual mandibular positions are variable, but some physiological conditions exist, which influence craniomandibular position. Consequently, in this study, we found that patients with TMD demonstrate a tendency for daytime airway collapse (Fig. 6). Woodson [24] investigated compliance during sedated sleep. Differences in compliance were reported, and retropalatal cross-sectional size was smaller during expiration on obstructed breaths. Our present study indicates that the SPR position opens the oropharyngeal isthmus in accord with the requirements for daytime phonation (Fig. 7). Moreover, the mean RV airway measurement with the phonetic bite or best found position (Fig. 8) appears to stabilize the airway during wakefulness (16% compared to 25% in Fig. 6), but this finding failed to reach statistical significance. In contrast, comparison of the SPR position at collapse (SPR–RV) with the non-SPR RV indicates upper airway enhancement by 12–15% (Fig. 9). Thus, use of a SPR protocol appears to have advantages that go beyond mandibular positioning and occlusal issues. Therefore, it can be suggested that a TMD orthotic fabricated to the SPR registration improves a patient's upper airway during the day, and these benefits may persist if the patient also wears the TMD orthotic while sleeping. Presumably, the mechanisms of airway correction using a TMD orthotic are similar to those of mandibular advancement devices, as it is thought that smaller upper airways probably predispose to

airway collapse during sleep [25]. Further studies will evaluate the oropharyngeal airway at different phonetic positions and using alternative jaw registration methods.

References

1. Miralles R, Dodds C, Palazzi C, Jaramillo C, Quezada V, Ormeno G, Villegas R (2001) Vertical dimension. Part 1: comparison of clinical freeway space. *Cranio* 19:230–236
2. Pound E (1977) Let /S/ be your guide. *J Prosthet Dent* 38:482–489
3. Burnett CA, Clifford TJ (1993) Closest speaking space during the production of sibilant sounds and its value in establishing the vertical dimension of occlusion. *J Dent Res* 72:964–967
4. Kamal I (2004) Test–retest validity of acoustic pharyngometry measurements. *Otolaryngol Head Neck Surg* 130:223–228
5. Singh GD, Clark WJ (2001) Localization of mandibular changes in patients with class II division 1 malocclusions treated with twin-block appliances: finite element scaling analysis. *Am J Orthod Dentofac Orthop* 119:419–425
6. Singh GD (2006) Digital diagnostics: three-dimensional modeling. *Br J Oral Maxillofac Surg* 23 (in press)
7. O'Higgins P (1999) In: Chaplain MAJ, Singh GD, McLachlan JC (eds) *On growth and form: spatio-temporal patterning in biology*. Wiley, England
8. Bassi F, Schierano G, Marinacci M (1999) Preliminary study of the behavior of the rest position and the minimum phonetic distance in edentulous patients rehabilitated with prostheses with modification of the palatal thickness. *Minerva Stomatol* 48:21–27 (article in Italian)
9. Faber CE, Grymer L (2003) Available techniques for objective assessment of upper airway narrowing in snoring and sleep apnea. *Sleep Breath* 7:77–86
10. Viviano JS (2004) Assessing orthotic normalization of pharyngeal dynamics. *Cranio* 22:192–208
11. Singh GD, Levy-Bercowski D, Santiago PE (2005) Three-dimensional nasal changes following nasolabial molding in patients with unilateral cleft lip and palate: geometric morphometrics. *Cleft Palate Craniofac J* 42:403–409
12. Singh GD, Maldonado L, Thind BS (2005) Changes in the soft tissue facial profile following orthodontic extractions: a geometric morphometric study. *Funct Orthod* 22:34–40
13. Okeson J (1989) *Management of temporomandibular disorders and occlusion*. Mosby, St. Louis
14. Burnett CA, Clifford TJ (1992) A preliminary investigation into the effect of increased occlusal vertical dimension on mandibular movement during speech. *J Dent* 20:221–224
15. Souza RF, Compagnoni MA (2004) Relation between speaking space of the /s/ sound and freeway space in dentate and edentate subjects. *Pesqui Odontol Bras* 18:333–337
16. Konchak PA, Thomas NR, Lanigan DT, Devon R (1987) Vertical dimension and freeway space. A kinesiographic study. *Angle Orthod* 57:145–154
17. Rivera-Morales WC, Mohl ND (1990) Anteroposterior and mediolateral variability of the closest speaking space. *Int J Prosthodont* 3:179–184
18. Lu GH, Chow TW, So LK, Clark RK (1993) A computer-aided study of speaking spaces. *J Dent* 21:289–296
19. Meier B, Luck O, Harzer W (2003) Interocclusal clearance during speech and in mandibular rest position. A comparison between different measuring methods. *J Orofac Orthop* 64:121–134
20. Lau KU (2004) The effect of orthotic devices on freeway space. *Cranio* 22:320–324

21. Johnson A, Wildgoose DG, Wood DJ (2002) The determination of freeway space using two different methods. *J Oral Rehabil* 29:1010–1013
22. Konchak PA, Thomas NR, Lanigan DT, Devon RM (1988) Freeway space measurement using mandibular kinesiograph and EMG before and after TENS. *Angle Orthod* 58:343–350
23. Woda A, Pionchon P, Palla S (2001) Regulation of mandibular postures: mechanisms and clinical implications. *Crit Rev Oral Biol Med* 12:166–178
24. Woodson BT (2003) Expiratory pharyngeal airway obstruction during sleep: a multiple element model. *Laryngoscope* 113:1450–1459
25. Arens R, Marcus CL (2004) Pathophysiology of upper airway obstruction: a developmental perspective. *Sleep* 1:997–1019